



SAW THE WAY FOUNDATION.

PATIENT REGISTRATIN FORM FOR MEDICAL ASSISTANCE.

DATE:14-09-2024.

PATIENT DETAILS:

PATIENT'S NAME : Ujjawal Sharma

AGE: 10 yrs

GENDER : MALE

FATHER'S NAME: Mr. Rajesh Sharma

OCCUPATION:UNEMPLOYED

MOTHER'S NAME : MS. Preeti

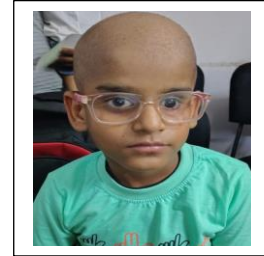OCCUPATION: HOME MAKER

SIBLING :1 Brother

FAMILY INCOME: NA

PATIENT SUFFERING FROM :EYE CANCER (RETINOBLASTOMA)

TREATMENTIS DONE AT :Aiims Hospital, New Delhi



PATIENT SUMMARY:

Ujjawal is suffering with life threatening disease of Eye Cancer and his treatment is going on AIIMS Hospital. Ujjawal's father doesn't able to fulfill his family's need. They are in very miserable situation currently, kindly help child for his chemotherapy and surgery treatment in which financial assistance required is Rs.1,50,000/-

DECLARATION:

I HEREBY DECLARE THAT THE INFORMATION GIVEN ABOVE IS TRUE AND TO THE BEST OF MY KNOWLEDGE.I AM NOT IN THE FINANCIAL POSTION TO ARRANGE FUNDS REQUIRED FOR THE TREATMENT OF MY CHILD.I AM FULLY AWARE OF THE FACT THE ORGANISATION WILL BE RAISING FUND FOR THE TREATMENT OF MY CHILD AND I HAVE NO OBJECTION WITH IT.

(SIGN OF THE FATHER/GUARDIAN)

निवेदन पत्र

सेवा में

श्री मान दूहि मधोव्य
सौंदर्य पाउंडेशन

मधोव्य सविनय निवेदन यह है कि मैं 11-62 वर्डि नं-3
गांव रांज, तहसील पादाड़ी, जिला - डीग भरतपुर
को निवासी है हमारे बच्चे को दोनो अंश में
वॉलेंट है एक आरंभ का अपरेशन हो चुका है और
दूसरी अंश इलाज चल रहा है डॉक्टर ने इलाज
का खर्चा 15,0000 का ~~स्व~~ बताया है जिसके इलाज
को खर्च के लिए हम असमर्थ हैं।
आपका आपसे निवेदन है कि आप हमारे बच्चे
को इलाज में सहयोग करेंगे

आपकी भविष्य की
मैं सदैव आपका बहुत आभारी रहूंगा,

धन्यवाद

प्रति

गांव - रांज
तहसील - पादाड़ी
जिला - डीग भरतपुर
राजस्थान

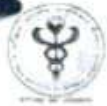ID: 101268094
 Dept No: 20150050106117
 Clinic No: 33/16
 UJJAYAL SHARMA
 NO: R LESH
 105 N
 Unit 17
 Room No: 107
 H NO-162 WARD NO-0 MAIN MAFFETRAH BARK
 K-AR (P) R. PATASTHAN N 1210.4 D/11A
 Mobile 9711887391

P. K.

Admit 7:30 am
 31/5/25
 ward 1A

नेत्र ईश्वरीय सर्वश्रेष्ठ उपहार है जिनका मनुष्य जीवन में दान करना परमश्रेष्ठ है।
 इनकी पूर्ण रक्षा कीजिए ताकि ये अपनी रक्षा कर सकें।

Eyes are God's most precious gift to man kind and eye donation is the most noble deed.
 Take full care of them so that they can take care of you.



अखिल भारतीय आयुर्विज्ञान संस्थान, नई दिल्ली-110029
ALL INDIA INSTITUTE OF MEDICAL SCIENCES, NEW DELHI -110029

आपातकालीन विभाग



(DEPT. OF EMERGENCY MEDICINE)

UHID No: 102107401

आपातकालीन नं. (Emergency No): 2025/030/0053791

दिनांक DATE: 14/05/2025

समय TIME: 02:54:27 PM

NON MLC

नाम NAME: MR. UJAWAL SHARMA

उम्र AGE: 10 years 1 months 4 days

लिंग SEX: M

S/O: RAJESH SHARMA

पता ADDRESS:

प्लॉट नं./ H No:

H-35 DEVLAL CITY GALI NO-1 SEC-7 GURGAON

गली / स्ट्रीट मोह

प्लॉट नं./ CITY BLOCK

पिन

राज्य STATE

HARYANA

दूरभाष नं. PHONE NO

मोबाइल नं. MOBILE NO

9711887391

स्थान Location

Paediatrics Emergency

किसने BROUGHT BY: Relative: MOTHER

Criticality: Red / Yellow / Green

Triage: Responsive

HR

/min

BP

mmHg RR

/min

SpO2

%

Unresponsive

Shifted to Paeds/ Main New Emergency

Presenting Complaints

6/1 RD (2 kids once)

① eye - enucleated

Received CT (SD (EV)) 10/5-11/5

Primary Assessment (ABCDE) Assessment Pentagon

no vomiting / headache x 2 days

oral ulcer x 2 days (also dysphagia)

Airway

Open & stable Yes No

Breathing RR 12/min

Efforts Normal Poor increased

Auscultation

Air entry

Normal/poor Differential

Added sounds

None/Stridor/Wheeze/Crackles

SpO2 on Room air 99%

Circulation

HR 124/min

CET 28 sec

BP 116/60 mmHg

Peripheral pulse: Poor Good

Central pulse: Poor Good

Skin temp Warm Cool

Others

Disability

GCS 15/15

Pupil size min

Pupillary Reactions Eye - 5m RTL

Motor activity

Normal & Symmetrical

Asymmetrical

Posturing Flaccidity Seizure

Blood Sugar mg/dl

Exposure

Temp 37.5°C

Colour Normal/pallor/cyanosis mottled

Any other skin lesions

Diagnosis

2 CINV

(No 8/10 7 ICP)

- Camula

- CBC

- VBC

- UT/RIT/SE

- fundus

- No cl/abn body movement/fever/seizure

- No l/po pain/abdo

- No fever

- accepting orally

3:40pm
~~DNST~~ DNST+1: 100 KCE @ 65 me/h
~~Day 4~~ Dexam 3.5 mg iv stat
~~Day 4~~ Enset 4 mg iv stat
 - Paide onco SR to review

Tanya Singh
 SR Paide

c/s/B Ped s Onco SR.

complete
R in 2011

K/C/O B/L RB.

(L) EORB - enucleated

(R) Group B - reactivated

c/o headache x 2 days

vomiting x 2 days.

c/o oral ulcers x 3 days

c/o constipation x 1 day.

C/E:-

HR - 118/min

RR - 20/min

CR 7<35 PP - 5V

Fundus Examination

to n/o

Papilledema No c/o

Chest -

clear

dehydration as -

Oral

P/A -

S, S, F

Mucositis
Grade 1

ems -

soft

W.N.

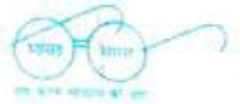To n/o CBC, VBG
LF T/KF1



अ० भा० आ० सं० अस्पताल / A.I.I.M.S. HOSPITAL

बहिरंग रोगी विभाग / Out Patient Department

अस्पताल के अंदर धूम्रपान करना है। / SMOKING IS PROHIBITED IN HOSPITAL PREMISES



बाल चिकित्सा विभाग

UHID: 102107401

कमरा / Room
C-210

OPR-6

Queue /
संख्या

F32

Dept No: 20190330026473

Unit-III, Paediatric

बहिरंग रोगी संख्या / O.P.D. Regn. No.

UJAYAL SHARMA

DR. RAJESH SHARMA

DR. M210, M-210

DR. JAYAL SHARMA, 3rd FLOOR, SEC-7

DR. JAYAL SHARMA, 3rd FLOOR, SEC-7

DR. JAYAL SHARMA, 3rd FLOOR, SEC-7

DR. JAYAL SHARMA, 3rd FLOOR, SEC-7

बुध, शनि, Wed, Sat



Reporting: 09 15 08
03/05/2025

निदान / Diagnosis

दिनांक / Date

उपचार / Treatment

(R) eye reactivated group B RB
for report

12. → $\frac{2160}{4190}$ 3.24L

CDW = Prof Dr R. Sethu
mam

RFT/CFT

→ do PET

→ PET scan → non-metastatic

↓
give SDCEV

→ to come to daycare on 5/5/25
at 9am

Dr. Renu for pedonc. → EANKIDS → will assist for PET
from 5/5/25 at 9am

CLEAN AND GREEN AIIMS / एम्स का यही संकल्प, स्वच्छता से काया कल्प

अंगदान-जीवन का बहुमूल्य उपहार / ORGAN DONATION - A GIFT OF LIFE

O.R.B.O., AIIMS, 26588360, 26593444, www.orbo.org Helpline - 1060 (24 hrs service)



ब० रो० वि० कार्ड
O.P.D. Card



अनुभाग व दिन
Section and Day
बुधवार व शनिवार
& Saturday

कमरा नंबर
Cabin No.

DR. RAJENDRA PRASAD CENTRE FOR OPHTHALMIC
SCIENCES

UHID: 181268094

Dept. No: 20150050106117

UJJWAL SHARMA

5Y/M

S/O: RAJESH

Date: 10/12/2016

General

RPC OPD-Dr. Bhavna
Chawla

Unit-VI

WED, SAT

Room No.: 32

Address: H-35 DEVILAL COLONY GALI NO 1 SEC 7 GURGOAN,
HARYANA, INDIA

Mobile: 9711887391



एकक
Unit

पता
Address

निदान

DIAGNOSIS

उपचार Treatment

(12) Regressed group B RB
(1) Brncheated

(151) optos CP. (RB) done OP2
30/11/25

SS OCT < through macula done
through lesion + upon-1

optos OCT through lesion

(142) 2pm

स कार्ड को सुरक्षित रखें तथा अस्पताल में दिखाने के समय हर वक्त साथ लायें।
Kindly keep this Card safely and bring it on your follow-up visits.

निषेध २. कूड़ा कर्कट केवल कूड़ेदान में ही डालें ३. थूकिये नहीं

ht
weight

1974

CEV today

125.4
23.5g

B14 0.9

Day 1 Lys v R

Lys carboplatin

" Etoposide.

D 2.

already
with by
Lys carboplatin
Etoposide

Pres

T. Septem 3/4. EOD

(SEPTAN
DS)

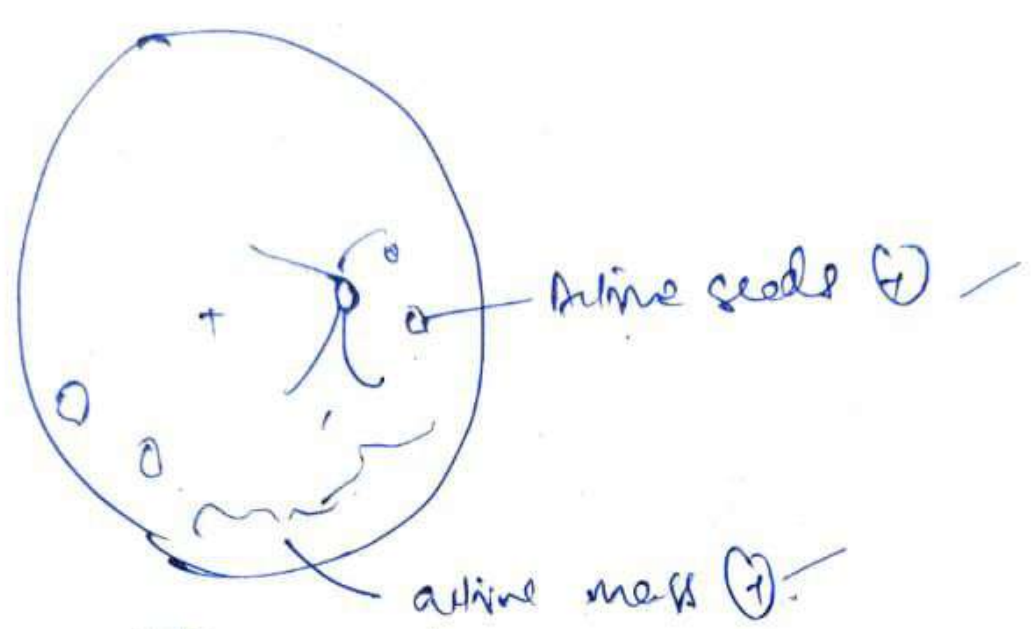
1yp Emset. (20g 15ml) 10ml + 10s

1yp Rem (250/5) 5ml 10s

5/4/25

(A) VA G/R → NFI.

- (A) Reestimated cup & RB
- (C) Emulated for EDB.



Adv
US/B on horn
To go for another 2 cycles of theme

5/5/2025

(A) VA: 4/18 → NFI

US/B Prof Bhavne

plan for IAC.
- to consider 1-2 cycles of theme
until IAC is done.
Also only security eq.



Accession No.	16251500	Registration Date	05/05/2025 11:22:13
Patient ID	P16100014795	Sex / Age	Male 10 Yrs 15 Days
Patient Name	Mst. UJJAWAL SHARMA	Report Released on	06/05/2025 08:22:40
Client Name	CANKIDS	Aadhar/ Passport No	
Ref. By	Mr. CANKIDS		

No significant FDG avid supraclavicular lymphadenopathy.

Few mild FDG avid and Non FDG avid subcentimeter to centimeter sized bilateral axillary lymphnodes, most with preserved fatty hilum are seen - likely inflammatory.

Thorax: -

The heart and the mediastinal vascular structures are well opacified with I/V contrast. The trachea and main bronchi appear unremarkable.

Both lung fields appear unremarkable. No focal abnormal FDG uptake is noted in the lung parenchyma.

No obvious pleural thickening / effusion seen.

No significant FDG avid mediastinal lymph nodes.

Thymus appears bulky with diffuse increased FDG uptake - likely physiological.

Abdomen and Pelvis: -

Liver is mildly enlarged in size (13.0 cm) with diffuse fatty infiltration. No significant focal lesion / abnormal increased FDG uptake is seen. Intrahepatic biliary radicals are not dilated. Portal and hepatic veins appear unremarkable.

Non FDG avid ill defined hypodensity is noted in the spleen - likely contrast attenuation differences.

Gallbladder, pancreas, adrenals glands and bilateral kidneys appear unremarkable. (USG is the modality of choice to evaluate for cholelithiasis/choledocholithiasis).

Few subcentimeteric Non FDG avid and minimal FDG avid mesenteric lymphnodes are noted - likely Inflammatory.

There is no ascites.

The stomach, small and large bowel loops appear normal in calibre and fold pattern and show physiological FDG distribution.



Dr. Rajendra Prasad Centre For Ophthalmic Sciences
ALL INDIA INSTITUTE OF MEDICAL SCIENCES (AIIMS), New
Delhi, 110029

Discharge Report
PROVISIONAL DISCHARGE CERTIFICATE

UHID : 101268094
Name: Mr. UJJAWAL SHARMA
Age/Sex: 10 years 2 months 10 days M
Ward Name: RPC 1A
Address: H. NO. 167 WARD NO. 04 BAHU, MARKET
RAWHAL, SHARADAPUR, GAZIABAD,
U.P. 201001
Mobile No: 9811887491
Date of Admission: 17/05/2025 14:10:47 AM
Date of Discharge: 19/06/2025 00:16:00 PM
No. R-023507-25
Department: R. P. Centre (Eye Centre)
Unit: Unit-VI
Bed No: 128
Other Allergy, if any :- []

ICD Code: I69.7
ICD Description: Malignant hypertension

Diagnosis
REFRACTATED GROUP 1 RBL
AND GROUP 2 FOR GROUP 1

Investigation
Systemic: BP 140/90
Ocular: I/A
RE 6/18
IOP
RE 16 MMHG

Treatment/Operative Procedure
Surgeon: Dr. R. P. Centre
Date: 30/05/2025
RE TAC SINGLE DRUG UNDER GA

Condition at Discharge
Vision: RE 6/18
Anterior Seg: BP
OPHA 0.004
AFTER 10
FUS 1.004
IOP: 10
RE 20/20
Anterior Seg: RE GLOW PRESENT

Advice During Discharge
Oral
Follow Up: 21/7/2025 at 2pm in
142B
Off EVA after 3 wks
for TTT augmentation

Prepared By: Dr. Pooja Yadav Ophthalmology

Signature Of Senior Resident

Date & Time

ब. रो. वि. कार्ड
O.P.D. Card

दुष्टि



येन अस्पताल पर्यटन हे
जो समय को ले-कराये हे

अनुभाग व दिन
Section and Day VI
बुधवार व शनिवार
Wednesday & Saturday

कमरा नंबर
Cabin No.

128

डा. राजेन्द्र प्रसाद नेत्र विज्ञान केन्द्र

अ. भा. अ.

Dr. Rajen

A.I.I.M.S.

यू.एच.आ

UHID N

Name



UHID: 101268094

ABHA:

Dept No: 20150050106117

Clinic No: 36820/2015

उज्जवला / UJJAWAL SHARMA

संख्या / Queue 18

कमरा / Room: 32

Unit-VI

RPC OPD

Dr. Bhavna Chawla

WED, SAT

बुध, शनि



Registration time:

17/05/2025 10:14:39 AM

S/O R. JESH

10Y 2M D M पुरुष

H. NO. 162 WARD NO-03 MAIN MARKET

RANIPUR, RANIPUR BHARATPUR, RAJASTHAN

Mob: 9711897391 General Rs. 0

Follow Up Patient

दिनांक

DATE

निदान

DIAGNOSIS

17 MAY 2025

उपचार Treatment

② Emulabed

② Reattached Cap B.

Ad

② IAC → single drop

② Chaul

डॉ. भावना चावला / Dr. BHAVNA CHAWLA
आचार्य नेत्र विज्ञान
Professor of Ophthalmology
डॉ. राजेन्द्र प्रसाद नेत्र विज्ञान केन्द्र
Dr. R.P. Centre for Ophthalmic Sciences
अ. भा. अ. नई दिल्ली / A.I.I.M.S., New Delhi-29

कृपया इस कार्ड को सुरक्षित रखें तथा अस्पताल में दिखाने के समय हर वक्त साथ लायें।

Kindly keep this Card safely and bring it on your follow-up visits.

1. भूषण निषेध 2. कूड़ा कर्कट केवल कूड़ेदान में ही डालें 3. थूकिये नहीं

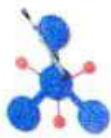1. No Smoking

2. Use Dustbin

3. No Spitting

114
MSSD
Please

UPPLTPO. Kindly
admit the
finances at
17/5/25



Accession No.	16251500	Registration Date	: 05/05/2025 11:22:13
Patient ID	P16100014795	Sex / Age	: Male 10 Yrs 15 Days
Patient Name	: Mst. UJJAWAL SHARMA	Report Released on	: 06/05/2025 08:22:40
Client Name	: CANKIDS	Aadhar/ Passport No	:
Ref. By	: Mr. CANKIDS		

DIGITAL WHOLE BODY PET CT

Clinical History: Known case of retinoblastoma. Post surgery, chemotherapy and radiotherapy (2016) status. Now presenting with recurrence in right eye. PET/CT study for disease status evaluation.

Procedure: 3.9 mCi of ^{18}F -fluorodeoxyglucose was administered intravenously. To allow for distribution and uptake of radiotracer, the patient was allowed to rest quietly for 60 minutes in a shielded room. Imaging was performed on an integrated 80-slice PET/CT scanner (UMI 550). CT images for attenuation correction and anatomic localization followed by PET images from vertex to mid-thigh were obtained. SUVmax was normalized to body weight SUVmax bw. Serum Creatinine and blood glucose was 0.5 mg/dL and 111 mg/dL respectively. CT scanning was performed using non-ionic intravenous and oral contrast. No adverse reaction was observed during the scan.

Observations:

Brain and orbits: -

Post left eye enucleation status. No significant metabolically active soft tissue thickening noted at the post operative site. Left eye ball prosthesis is noted.

FDG avid heterogeneously enhancing irregular soft tissue density nodular lesion is noted in the posterior chamber of right eyeball in the inferolateral quadrant measuring 0.8x1.2cm, SUV max: 9.5. The lesion is closely abutting the adjoining rectus muscle. No obvious intraconal / extraconal extension of the lesion is noted.

Normal physiological radiotracer distribution noted in the brain parenchyma. No focal lesion or abnormal FDG uptake noted in the brain.

(NOTE: If there is a strong suspicion for brain metastases / lesion, then MRI is suggested for further evaluation, as small lesions may not be detected on an FDG PET/CT study due to normal high physiological uptake in the brain).

Head and Neck: -

Physiological FDG uptake is noted in vocal cords.

Bulky bilateral tonsils and adenoids are noted with increased FDG uptake - likely inflammatory.

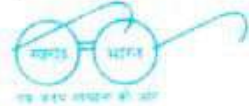Nasopharynx, oropharynx, hypopharynx and larynx appear unremarkable with no significant abnormal FDG uptake in relation to them.

Thyroid gland appears unremarkable with no focal abnormal FDG uptake.

Minimal FDG avid bilateral level Ib and II cervical lymphnodes are seen - likely inflammatory.



अ० भा० आ० सं० अस्पताल / A.I.I.M.S. HOSPITAL बहिरंग रोगी विभाग / Out Patient Department



अधिका विभाग
UHD: 10210740

कमरा / Room
C-217

Queue /
संख्या **F51**

OPR-6

Dept No: 20160930028473
Clinic No: 2016/PCSC/1096

Unit-I, PCSC PAEDS

ARAVI SHARMA

वॉरंविण पजीकृत सं० / O.P.D. Regn. No.

DR RAJESH SHARMA
MD DM 28D / M (पुरुष)

35 DEVI LAL CLY GALI NO-1 SEC-7
MARGAON HARYANA INDIA
PH: 9711067201 General Rx: 0
Follow Up Patient



निदान / Diagnosis

दिनांक / Date

23 kg.

उपचार / Treatment

C/O - R regressed gp BRB

① enucleated

(Sx/RT/Uterus)

→ Rx completed in Dec 2016

initial Rx

240CEV

↓

① enucleation

↓

1040-CEV

RT ⇒ 4047/28 yue

30/5/2016 to 22/6/16

C/O/w Pres. R. & Th

TO

RPC

This patient completed treatment in December 2016.

Repeat EUA S/O reactivated gp BRB right eye.

Kindly consider urgent local chemo/therapy for the reactivation. for eye salvage as vision is intact.

DR. ARAVI SHARMA
Ophthalmologist
All India Institute of Medical Sciences
New Delhi

N/V on 10/05/25

9 AM

ARAVI
J&P



CLEAN AND GREEN AIIMS / एम्स का यही संकल्प, स्वच्छता से काया कल्प
अंगदान-जीवन का बहुमूल्य उपहार / ORGAN DONATION - A GIFT OF LIFE
O.R.B.O., AIIMS, 26588360, 26593444, www.orbo.org Helpline - 1060 (24 hrs service)

